

HISTOLOGICAL AND IMMUNOHISTOCHEMICAL FEATURES OF DYSAUTONOMIA IN COMMERCIAL RABBITS AFFECTED BY INTESTINAL DISORDERS

Cornaggia M.^{1*}, Palazzolo L.¹, Di Castri A.¹, Vascellari M.², Tonon E.¹, Viel L.¹, Bano L.¹

¹ Veterinary Diagnostic Laboratory, Istituto Zooprofilattico Sperimentale delle Venezie, Vicolo Mazzini 4, Villorba (Treviso), 31020, Italy

² Histopathology Laboratory, Istituto Zooprofilattico Sperimentale delle Venezie, Viale dell'Università 10, Legnaro (Padova), 35020, Italy

*Corresponding author: mcornaggia@izsvenezie.it

ABSTRACT

Dysautonomia is a severe fatal gastro-intestinal disorder characterized by caecal impaction, anorexia, and depression. The disease has been reported in a wide range of animals such as horse, cat, dog, hare and rabbit. Histopathological findings are identified by degenerative damages of the autonomous nervous system, that can be evidenced by means of targeted immunohistochemical (IHC) techniques. Rabbits affected by dysautonomia showed a severe large intestinal paralysis that could be associated with the presence of *C. botulinum* in the gut, as already demonstrated in cats.

The aim of our work was to evaluate the presence of BoNT producing Clostridia in rabbit with gastro-intestinal disorders and to assess the neurological damages occurred in the gut by IHC techniques targeted on a neurodegenerative marker (synaptophysin). To this purpose, 66 live commercial rabbits with an intestinal disorder history were euthanized and necropsied. Gross lesions were categorized in two forms: cecal constipation (CC) and fluid entero-typhlitis (ET). BoNT producing Clostridia were not detected in the caecal contents. Degenerative lesions of the autonomous nervous system were detected in the 39.4% of the analyzed subjects.

The highest IHC positivity occurred in rabbits with CC suggesting that constipation could be mediated by a neurological damage of the myenteric plexa.

Further studies with healthy control rabbits with no gastro-enteric disorders are required to better understand the pathogenesis of dysautonomia and to investigate other etiological causes.

Key words: dysautonomia, synaptophysin, immunohistochemistry, *Clostridium botulinum*

INTRODUCTION

Dysautonomia (“grass sickness” or Key-Gaskell syndrome) is a neuropathological disease reported in horses (Gilmour, 1973), cats (Sharp *et al.*, 1984), dogs (Pollin and Sullivan, 1986), hares (Whitwell, 1991) and pet rabbits (Hahn *et al.*, 2005). The disease is characterized by a gastrointestinal hypomotility due to an extensive degeneration of the autonomic nervous system (Key and Gaskell, 1982) that can be evidenced by means of immunohistochemical procedures for the detection of markers of neurodegeneration. Cervical and abdominal ganglia and the digestive tract histopathology is commonly used for diagnostic purpose (Symonds *et al.*, 1995; Wehrli Eser *et al.*, 2000; Cave *et al.*, 2003). Synaptophysin, a calcium-binding glycoprotein (38 kD) involved in vesicles neurotransmission, is one widely used marker of neurodegeneration in domestic animals and humans since it is highly stored in degenerated neurons (Wiedenmann *et al.*, 1986; Dzienis-Koronkiewicz *et al.*, 2005; Hilbe, 1999; Hilbe *et al.*, 2005). Constipation due to hypomotility characterizes also the epizootic rabbit enteropathy (ERE), a highly lethal (30–80% mortality) disease of meat rabbits aged 6 to 14 weeks that still remains of unknown etiology. Botulinum neurotoxin (BoNT) type C has been significantly detected in the feces of cats affected by dysautonomia, in comparison with healthy cats (Nunn *et al.*, 2004). Up to date eight different BoNT-serotypes (A to H) are known (Peck *et al.*, 2016). The aim of this study was to investigate the pathological features of intestinal dysautonomia in commercial rabbits and to evaluate the role of BoNT producing Clostridia in the pathogenesis of this intestinal disorder.

MATERIALS AND METHODS

Sixty-six live fattening rabbits hosted in 27 commercial farms, aged 30 to 80 days, were sent to the Veterinary Diagnostic Laboratory of Treviso (Istituto Zooprofilattico Sperimentale delle Venezie) with clinical signs ascribable to gastro-intestinal disorders, referred also by the veterinary practitioner. The animals were humanely suppressed according to European and National Animal Welfare laws (EU reg. 2009/1099; EU dir. 2010/63) and subjected to post mortem examinations.

Intestinal anatomico-pathological findings were categorized in two macroscopic forms: caecal constipation (CC) and enterotyphlitis with fluid content in the cecum (ET). Caecal constipation was characterized by a dehydrated caecal content, firmly attached to the mucosal surface attributable to the paralysis of the large intestine.

One gram of caecal content was inoculated in fortified cooked meat medium (FCMM), heat shocked, and incubated anaerobically at 37 °C for 48 hours. FCMM broths were subsequently tested by means of PCR protocols targeted on BoNT-encoding genes types A to F (Anniballi *et al.*, 2011; Anniballi *et al.*, 2010).

Sixty-four pylorus and caecum tissue portions, 19 colon samples, 46 cranial mesenteric ganglia and 41 caudal mesenteric ganglia were sampled and stored in 10% buffered formalin for at least 24 hours, embedded in paraffin, routinely processed and stained with hematoxylin-eosin. Further 4- μ m sections underwent immunohistochemistry (IHC), using the monoclonal anti-mouse synaptophysin primary antibody. IHC results were categorized as follows: negative samples were assessed when synaptophysin was detected in neurons, in the ganglia cells and in the axons (Figure 1); positive samples were classified when synaptophysin was detected as granular red deposits in the neuronal cytoplasm (Figure 2).

The Chi-Square Test was applied to correlate the IHC positivity with at least one sample per subject with the anatomico-pathological picture (CC and ET). Fisher's Exact Test was employed to evaluate the correlation between IHC positivity within the single gut districts in both CC and ET forms. Statistical analyses were carried out with the online tool Social Statistics Calculator (<https://www.socscistatistics.com/>).

RESULTS AND DISCUSSION

According to the anatomico-pathological findings, 43 (65.2%) cases were classified as CC and 23 (34.8%) as ET. All samples resulted negative for BoNT producing Clostridia types A to F.

According to IHC findings, 26/66 subjects (39.4%) resulted positive: 16 showed CC (61.5%) and 10 ET (38.5%). This difference did not result significant ($p > 0.05$).

Neuronal degeneration (IHC positivity) was detected in 2/47 (4.3%) cranial mesenteric ganglia, 1/41 (2.4%) caudal mesenteric ganglia, 5/64 (7.8%) pyloric (gastric) plexus, 17/64 (26.6%) myenteric caecal plexus, 8/19 (42.1%) myenteric colic plexus. Three out of 26 subjects showed neuronal degeneration in more than one specimen. IHC positivity within the single gut districts in both CC and ET forms did not result significant ($p > 0.05$).

The aim of our study was to assess if dysautonomia plays a role in rabbit enteric disorders and if BoNT producing Clostridia may be involved in the pathogenesis of neurodegenerative lesions, as observed by other authors in a restricted number of subjects (Hahn *et al.*, 2005; Nunn *et al.*, 2004).

Our results demonstrate that a neuronal degeneration of mesenteric ganglia and/or of the myenteric plexa (dysautonomia) may occur in rabbits affected by gastrointestinal disorders.

This neuronal damage seems to be unrelated to the anatomico-pathological forms observed (CC vs ET), although this observation should be confirmed in a larger number of cases, including both affected and healthy subjects.

Synaptophysin IHC positivity was detected in both CC and ET. It cannot be excluded that those forms may represent two different pathological phases of the same disease.

The low number of mesenteric ganglia with neurodegenerative lesions suggests that those structures are less frequently affected than myenteric plexa and that the latter should be considered the target specimens for the diagnosis of dysautonomia in rabbit. This finding may be due to the fact that the

unknown degenerative cause originates from the intestinal lumen and reaches firstly the intramural intestinal nervous system (myenteric plexa).

BoNT encoding genes were not detected in the enrichment broths previously inoculated with the caecal contents. This finding seems to exclude the involvement of known BoNT producing Clostridia in the enteric disorders of commercial rabbits. Unfortunately, we do not have any information about possible antimicrobial treatments of the rabbits included in the study. Indeed, antimicrobial treatments could have destroyed the vegetative forms of BoNT producing Clostridia, reducing the possibility of their growth in the enrichment broth.

Further case-control studies are required to better understand the role of neuro-degenerative lesions in rabbit intestinal dysautonomia.

CONCLUSIONS

Our results demonstrate that dysautonomia should be considered in the diagnosis of rabbit enteric diseases and that synaptophysin is a good marker of myenteric plexa degeneration.

The highest IHC positivity occurred in rabbit with CC suggests that constipation can be mediated by a neurological damage of the autonomous intestinal nervous system.

In contrast with other studies that had associated the dysautonomia with the presence of *C. botulinum* type C in the gut, our findings seem to exclude its presence in the analyzed rabbits affected by enteric disorders. However, further investigation concerning this possible etiology should be performed in untreated subjects at the beginning of the clinical signs in order to avoid the possible interference in the detection of *C. botulinum* due to the therapy with antimicrobials.

REFERENCES

- Anniballi F., Auricchio B., Woudstra C., Fach P., Fiore A., Skarin H., Bano L., Segerman B., Knutsson R., and De Medici D. 2013 Multiplex Real-Time PCR for Detecting and Typing *Clostridium botulinum* Group III Organisms and Their Mosaic Variants *Biosecurity and Bioterrorism: Biodefense Strategy, Practice, and Science Volume 11, Supplement 1*.
- Cave, T. A., Knottenbelt, C., Mellor, D. J., Nunn, F., Nart, P. and Reid, S. W. J. 2003 Outbreak of dysautonomia (Key-Gaskell syndrome) in a closed colony of pet cats. *Veterinary Record*, 153, 387–392.
- Dzienis-Koronkiewicz E., Debek W. and Chyczewski L. 2005 Use of synaptophysin immunohistochemistry in intestinal motility disorders. *Eur J Pediatr Surg*. 2005 Dec;15(6):392-8.
- Gilmour JS. 1973 Observations on neuronal changes in grass sickness of horses. *Res Vet Sci*. Sep;15(2):197-200.
- Guscetti, F., Pospischil, A., Läubli, C. and Ehrensperger, F. 1991 Pathomorphologie der feline Dysautonomie (Key-Gaskell-Syndrom). Histologische, elektronenmikroskopische und immunhistologische Befunde bei 4 Katzen. *Tierärztliche Praxis*, 19, 296–301.
- Hahn C. N., Whitwell K. E., Mayhew I. G. 2005. Neuropathological lesions resembling equine grass sickness in rabbits. *Veterinary Record*, 156:778-779.
- Hilbe M, Guscetti F, Wunderlin S, Ehrensperger F. 2005 Synaptophysin: an immunohistochemical marker for animal dysautonomias. *J Comp Pathol*. Feb-Apr;132(2-3):223-7.
- Hilbe, M., Wunderlin S., and Ehrensperger F. 1999 Synaptophysin—an immunohistochemical marker for detection of neuronal degeneration in equine grass sickness. In: Proceedings of the 17th Congress of the *European Society of Veterinary Pathology*, Nantes, p. 210 (abstract).
- Nunn, F., Poxton, IR., Cave, TA., Knottenbelt, C. 2004 Association between Key-Gaskell syndrome and infection by *Clostridium botulinum* type CID *Veterinary Record* 155, 111-115.
- Oglesbee BL., Lord B. 2020 Gastrointestinal Diseases of Rabbits. *Ferrets, Rabbits, and Rodents*.;174-187.
- Peck, M. W., Smith, T. J., Anniballi, F., Austin, J. W., Bano, L., Bradshaw, M., Cuervo, P., Cheng, L. W., Derman, Y., Dorner, B. G., Fisher, A., Hill, K. K., Kalb, S. R., Korkeala, H., Lindström, M., Lista, F., Lúquez, C., Mazuet, C., Pirazzini, M., Popoff, M. R. and Stringer, S. C. 2017 Historical Perspectives and Guidelines for Botulinum Neurotoxin Subtype Nomenclature. *Toxins*, 9 (1), 38.
- Pollin M, Sullivan M. 1986 A canine dysautonomia resembling the Key-Gaskell syndrome. *Vet Rec*. Apr 5;118(14):402-3.
- Sharp, N.J.H., Nash, A.S. And Griffiths, I.R. 1984 Feline dysautonomia (the Key - Gaskell syndrome): a clinical and pathological study of forty cases. *Journal of Small Animal Practice*, 25: 599-615.
- Symonds, H. W., McWilliams, P., Thompson, H., Nash, A., Sanchez, S. and Rozengurt, N. 1995 A cluster of cases of feline dysautonomia (Key-Gaskell syndrome) in a closed colony of cats. *Veterinary Record*, 136, 353–355.

- Wehrli Eser, M., Feige, K. and Hilbe, M. 2000 Klinische Symptomatik und Diagnostik bei Pferden mit akuter Grass sickness in der Schweiz und in Süddeutschland. *Pferdeheilkunde*, 16, 138–143.
- Whitwell KE. Do hares suffer from grass sickness? *Vet Rec.* 1991 Apr 27;128(17):395-6.
- Wiedenmann B, Franke WW, Kuhn C, Moll R, Gould VE.1986 Synaptophysin: a marker protein for neuroendocrine cells and neoplasms. *Proc Natl Acad Sci U S A. May;83(10):3500-4.*

PHOTOGRAPHS

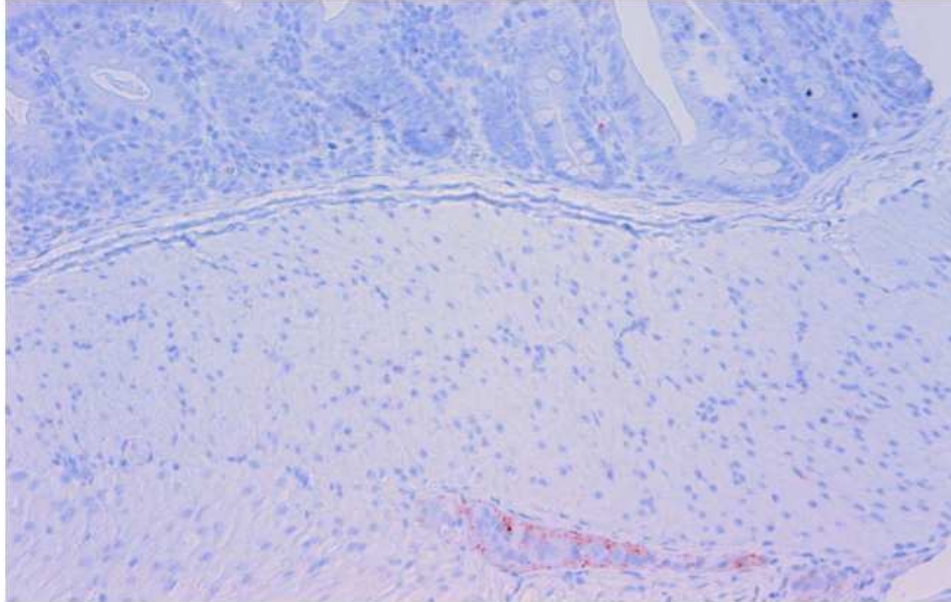


Figure 1 "IHC- Synaptophysin negative control. Myenteric plexus, positivity is recorded only within the neuron membrane"

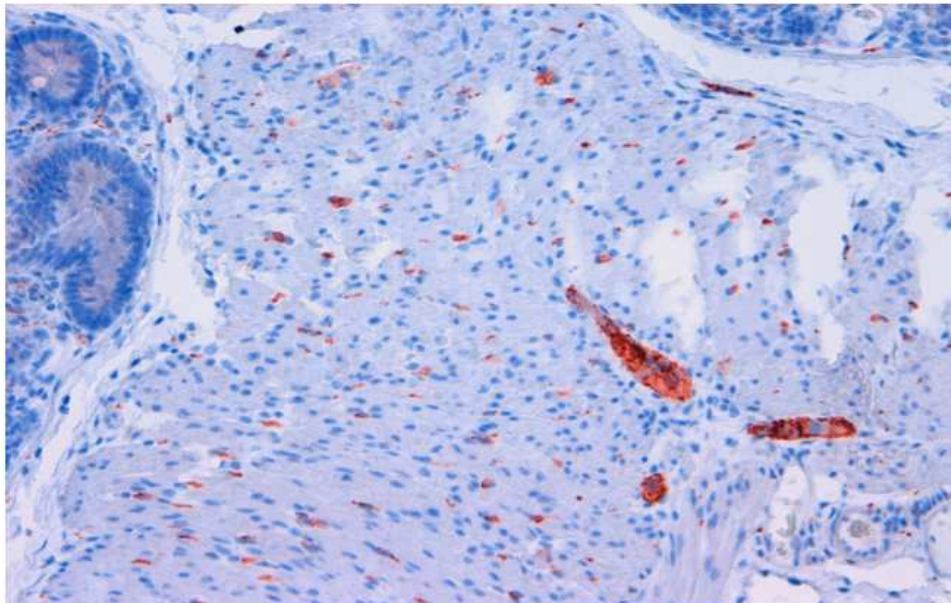


Figure 2: "IHC with monoclonal antibody Synaptophysin. Neurodegenerative lesion of Colic myenteric plexus".